

Bypass gástrico laparoscópico con gastrectomía subtotal: Una Modificación Técnica en un Paciente con Metaplasia Intestinal de la Mucosa Gástrica

Laparoscopic Gastric Bypass with Subtotal Gastrectomy: A Technical Modification in a Patient with Intestinal Metaplasia of the Gastric Mucosa

Laparoscopic Gastric Bypass with Subtotal Gastrectomy: A Technical Modification in a Patient with Intestinal Metaplasia of the Gastric Mucosa

SUMMARY: Laparoscopic Roux-en-Y gastric bypass (LRYGB) is one of the most frequently performed bariatric procedures worldwide. Although rare, there are some reports concerning the risk of developing cancerous lesions in the excluded remnant stomach.


We report the case of a patient who was proposed for a REDO surgery due to persistent complaints of heartburn after performing a sleeve gastrectomy. The pathology report had shown the presence of intestinal metaplasia on the sleeve's operative specimen, therefore we have performed a modification to the classic LRYGB technique – a laparoscopic gastric bypass with subtotal gastrectomy. This technical change precludes leaving a segment of excluded stomach, which would become inaccessible for endoscopic evaluation.

Although several factors seem to render a decreased risk of malignancy involving the excluded segment, there are reported cases of cancer development in the gastric remnant. These malignancies are generally associated with delayed diagnosis and poor prognosis, since initial symptoms are often nonspecific, and the study of the excluded stomach is challenging.

In this case, the post-operative period was uneventful and the patient had full resolution of her heartburn symptoms. There were also no

differences concerning the metabolic effects of surgery during the follow-up period.

KEYWORDS: Roux-en-Y Gastric Bypass, Subtotal gastrectomy, Gastric cancer, Intestinal metaplasia



bmi journal
seco-seedo

INTRODUCTION:

Obesity has become a major public health problem all over the globe, with approximately one third of the world's population being overweight or obese.

Laparoscopic Roux-en-Y gastric bypass (LRYBG) is one of the most frequently performed bariatric procedures worldwide. Although rare, there are some reports in the literature concerning the risk of developing complications, such as cancerous lesions, in the excluded remnant stomach. The management of these cases remains a challenge for the bariatric surgeon and are often associated with delayed diagnosis and a poor prognosis.⁽¹⁾

CASE REPORT:

■ Case presentation:

We report the case of a 54-year-old female, with a personal history of Hypertension, Dyslipidemia, Asthma, Depression, Fibromyalgia, Osteoarthritis and a previous sleeve gastrectomy.

On her initial evaluation in our Bariatric Surgery Unit, before performing the sleeve gastrectomy, the patient had a Body Mass Index (BMI) of 37.7 kg/m² and presented a "Volume Eater" eating pattern.

The pre-operative workup comprehended: laboratory studies, with an evaluation of vitamin and ionic status; *Helicobacter pylori* (HP) fecal antigen testing; a chest radiograph; electrocardiogram and echocardiogram; an abdominal ultrasound and an

esophagogastroduodenoscopy (without biopsy). These studies didn't show any abnormalities.

During her pre-operative evaluation period the patient presented a 5 kg weight reduction. She was then proposed for a sleeve gastrectomy.

The pathological examination of the operative specimen revealed signs of moderate, active chronic gastritis, focal intestinal metaplasia, and a few HP on the crypts, which lead to the prescription of eradication therapy.

Eight months after surgery, the patient developed persistent complaints of heartburn, which were not present before. A radiological study was performed, which confirmed the presence of "de novo" Gastroesophageal Reflux Disease. As these symptoms persisted even after HP eradication and one year of therapy with proton pump inhibitors, a REDO surgery was proposed. The patient had at this time a BMI of 25.1 kg/m² (with a percentage of excess weight loss of 99.3% since the sleeve gastrectomy).

However, considering the finding of intestinal metaplasia on the operative specimen, the team decided to perform a modification to the classic Roux-en-Y gastric bypass (RYGB) technique, thus avoiding to leave a segment of excluded stomach which would become inaccessible for future endoscopic evaluation.

▪ **Surgical technique:**

The patient was placed in supine position, with abducted legs. Three 5 mm and two 12 mm trocars were used. (Figure 1)

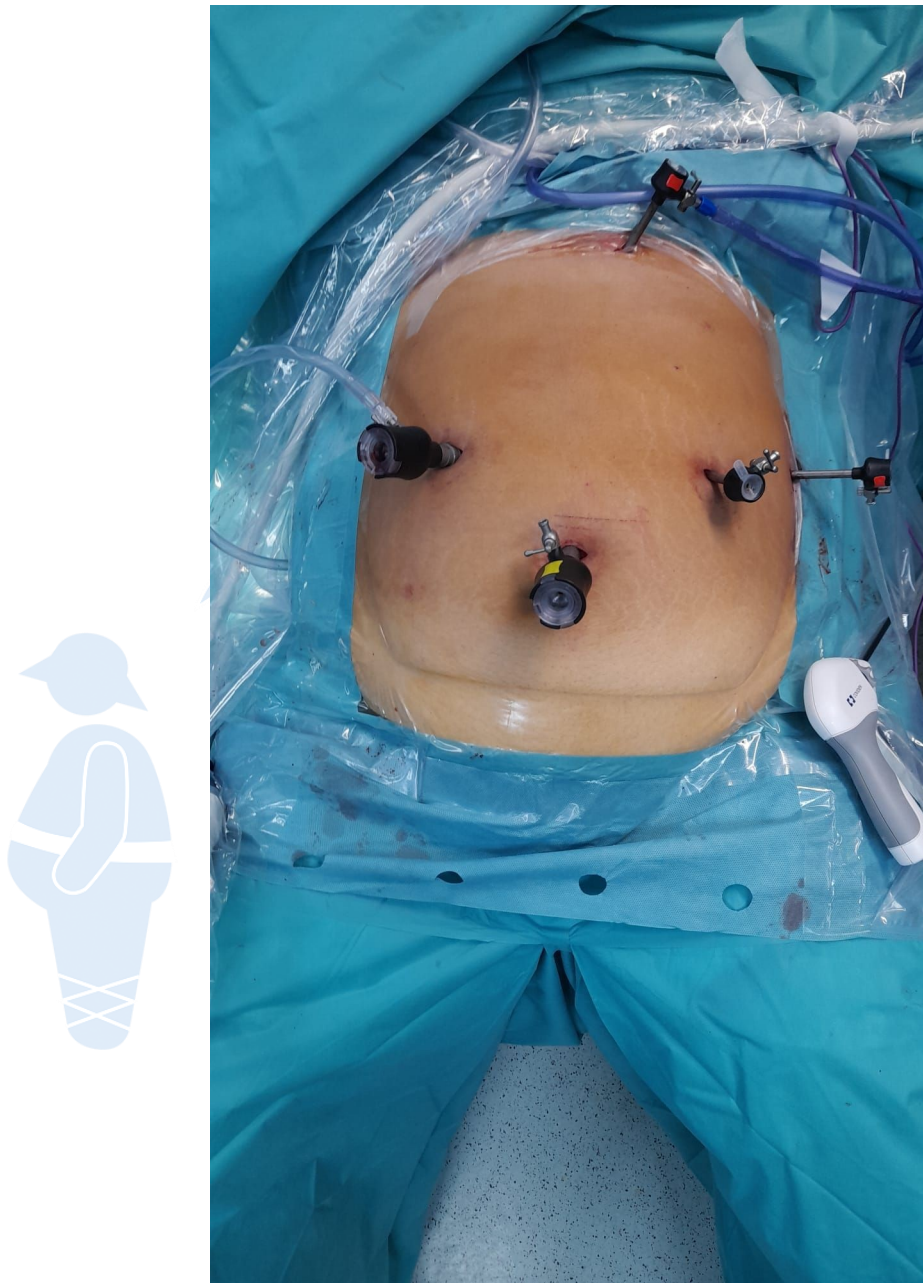


Figure 1 - Patient positioning and trocar placement

We began the procedure by taking down adhesions from the previous surgery along the gastropasty up to the left diaphragmatic crus, followed by dissection of the posterior gastric surface. We have then identified the pylorus and sectioned the duodenum immediately distal

to it using an iDrive™ Stapler (reinforced purple cartridge with stapler size: 3 mm, 3.5 mm and 4 mm). We proceeded to the dissection along the small curvature, ligating the right and left gastric vessels with a Ligasure™ device, up to the level of the second gastric vein.

The gastropasty was sectioned transversely with the iDrive™ Stapler (purple cartridge with stapler size: 3 mm, 3.5 mm and 4 mm). The biliary loop was measured counting 80 cm from the angle of Treitz and a gastrojejunal anastomosis – calibrated by a 36 French gastric tube – was then performed on the posterior surface of the gastric pouch, using the iDrive™ Stapler (tan cartridge with stapler size: 2 mm, 2.5 mm and 3 mm). (Figure 2)

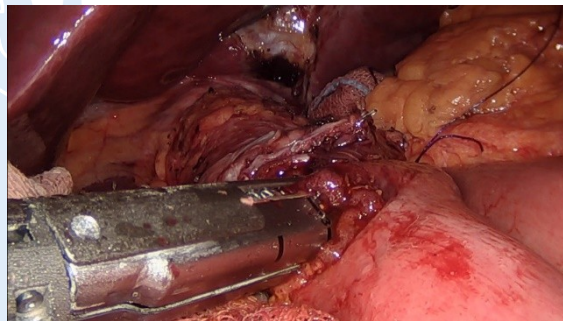


Figure 2 - Gastrojejunal anastomosis

The Petersen defect was closed with a continuous suture, using a non-absorbable, braided, and coated suture material, made of polyester fibers.

Afterwards, a latero-lateral anastomosis between the alimentary limb, measured to approximately 160 cm (according to the team's usual practice at the time) and the biliary loop was created using the iDrive™ Stapler (tan cartridge with stapler size: 2 mm, 2.5 mm and 3

mm). The patency of both anastomoses was then tested with methylene blue.

Finally, the mesenteric defect was also closed with a continuous suture, using a non-absorbable, braided and coated polyester suture material. The jejunum between the two anastomosis was sectioned using the iDrive™ Stapler (tan cartridge with stapler size: 2 mm, 2.5 mm and 3 mm), thus creating a Roux-en-Y configuration. Two suction drains were left in place and the operative specimen was removed.

▪ **Outcomes:**

The post-operative period was uneventful, and the patient had full resolution of her heartburn symptoms.

The Pathological report of the operative specimen confirmed the presence of multifocal intestinal metaplasia.

DISCUSSION:

As the number of RYGB procedures performed annually continues to rise, there has been a growing concern about the detection of lesions that might arise in the excluded stomach, namely neoplastic lesions.

In Portugal, gastric cancer is the sixth most common malignancy and the third cause of cancer-related death.⁽²⁾ The importance of identifying patients that may have an increased risk of developing gastric cancer is well recognized by several groups.

The sequence by which gastric cancer develops has been well described by Correa: chronic inflammation of the stomach mucosa

may lead to a cascade of mucosal changes that can progress to atrophic gastritis and intestinal metaplasia, followed by dysplasia and, finally, adenocarcinoma. As such, gastric atrophy and intestinal metaplasia are recognized as precancerous conditions, because they independently confer a risk for the development of gastric cancer.⁽³⁾

According to international guidelines, screening and surveillance of people at risk may decrease gastric cancer mortality by allowing early detection and treatment.⁽⁴⁾ In patients submitted to RYGB, the excluded stomach becomes inaccessible for endoscopic evaluation, hampering the surveillance of a patient with a known premalignant lesion.

Although it has been shown that overweight and obesity may be associated with an increased risk of cancer, the risk of developing a gastric neoplasm after bariatric surgery is not well established.

Concerning the patients submitted to LRYGB, there are several factors that seem to render a decreased risk of developing cancer in the remnant stomach. Inoue et al. described a protective effect of the anatomic changes provided by Roux en-Y-gastric bypass in a rodent model, namely by the prevention of direct contact between dietary carcinogens and the gastric mucosa, lower concentration of bacteria that may play a role in gastric carcinogenesis and lower bile reflux.⁽⁵⁾

However, in contrast to these findings, other studies show that - as a blind pouch - the remnant stomach is susceptible to high bacterial and fungal colonization and that bile content can be found in a significant percentage of patients. Additionally, there are reports

describing inflammatory changes found on the excluded segment, as well as intestinal metaplasia in patients with a previously normal esophagogastroduodenoscopy.^(6,7)

There are few data in the literature describing the development of gastric cancer on the remnant stomach after RYGB, and its true prevalence is unknown.⁽⁸⁾ In a systematic review by Lancellotti et al. seventeen case reports were found since 1991 - fifteen gastric carcinomas, one GIST and one lymphoma. These malignancies are generally associated with delayed diagnosis and poor prognosis, since initial symptoms are often nonspecific and may be attributed to the effects of surgery.⁽⁹⁾

As previously mentioned, the study of the excluded stomach poses a significant diagnostic challenge. Imaging studies as abdominal CT scan or endoscopic ultrasound may be useful to detect gastric wall thickening as well as lymphadenopathies or metastatic disease, however, these are all late findings in the natural history of the disease.

Direct examination may be possible with the use of advanced endoscopic techniques such as antegrade double-balloon enteroscopy or through a surgical-assisted trans-gastric endoscopy if a short limb loop is present. However, the use of these procedures has a limited availability, since they have elevated costs and may be technically challenging.⁽¹⁰⁾

In order to avoid the challenges of maintaining the surveillance and to prevent the development of pathology in the excluded stomach, we

have proposed to this patient to remove the bypassed segment in the same surgical time. This approach has also been described in other reports, and it was not associated with increased morbidity or mortality after surgery. It also presents similar results considering the 5-year weight loss when compared to the classic technique.^(11,12)

In this case, performing the resection of the excluded gastric segment was not associated with increased morbidity and, so far, we have not detected any differences concerning the metabolic effects of surgery during the follow-up period.

CONCLUSIONS:

With the increasing burden of obesity worldwide, the number of bariatric surgeries continues to rise each year and Roux-en-Y gastric bypass remains one of the most commonly performed procedures. However, the exclusion of a gastric segment - which becomes inaccessible for endoscopic study - especially in areas of high prevalence for gastric cancer, is becoming a concern to the bariatric surgeons. This question is particularly relevant in young patients, with a long-life expectancy, that have a known risk factor for developing a gastric neoplasm.

In this case report, we present our surgical option in a patient with pre-operative diagnosis of intestinal metaplasia, to whom we proposed the resection of the bypassed segment of the stomach in the same operative time. This strategy was not associated with

increased morbidity and eliminates the possibility of developing any subsequent pathology in the excluded stomach.

CONFLICTS OF INTEREST:

The authors declare that they have no conflicts of interest.

BIBLIOGRAPHY:

1. Magge D, Holtzman MP. Gastric Adenocarcinoma in patients with Roux-en-Y Gastric bypass: A case series. *Surgery for Obesity and Related Diseases*. 2015 Sep;11(5):e35-8.
2. Report on cancer - Portugal [Internet]. Lyon: Global Cancer Observatory; 2021 Mar [cited 2022 Nov 19] p. 1-2. Available from: <https://gco.iarc.fr/today/data/factsheets/populations/620-portugal-fact-sheets.pdf>
3. Spence AD, Cardwell CR, McMenamin ÚC, Hicks BM, Johnston BT, Murray LJ, et al. Adenocarcinoma risk in gastric atrophy and intestinal metaplasia: a systematic review. *BMC Gastroenterol*. 2017 Dec 11;17:157.
4. Pimentel-Nunes P, Libânio D, Marcos-Pinto R, Areia M, Leja M, Esposito G, et al. Management of epithelial precancerous conditions and lesions in the stomach (MAPS II): European Society of Gastrointestinal Endoscopy (ESGE), European Helicobacter and Microbiota Study Group (EHMSG), European Society of Pathology (ESP), and Sociedade Portuguesa de Endoscopia Digestiva (SPED) guideline update 2019. *Endoscopy*. 2019 Apr;51(4):365-88.
5. Inoue H, Rubino F, Shimada Y, Lindner V, Inoue M, Riegel P, et al. Risk of gastric cancer after Roux-en-Y gastric bypass. *Arch Surg*. 2007 Oct;142(10):947-53.
6. Cunha Medeiros A, Meneses Rego A, Medeiros Azevedo I, Ferreira Carvalho M, Brasil Medeiros V, Araujo-Filho I. Metabolism and gastric remnant changes after Roux-en-Y gastric bypass in rats. *J Invest Surg*. 2011;24(3):109-14.
7. Ribeiro MCB, Lopes LR, Coelho Neto J de S, Terciotti V, Andreollo NA. Gastric Adenocarcinoma after Gastric Bypass for Morbid Obesity: A Case Report and Review of the Literature. *Case Rep Med*. 2013;2013:609727.

8. Tornese S, Aiolfi A, Bonitta G, Rausa E, Guerrazzi G, Bruni PG, et al. Remnant Gastric Cancer After Roux-en-Y Gastric Bypass: Narrative Review of the Literature. *Obes Surg*. 2019 Aug;29(8):2609–13.
9. Francesco L, Muriel C, Marie D, Daniela C. Gastric Cancer After Roux-en-Y Gastric Bypass: A Case Report and a Systematic Review. *Journal of Surgery*. 2019 Nov 6;7(6):163.
10. Ali S, Chaar A, Frandah W, Altoos R, Sattar Z, Hasan M. Exploring the Excluded Stomach: A Case Series of Novel Endoscopic Techniques to Diagnose Gastric Cancer in the Excluded Stomach After Roux-en-Y Gastric Bypass Surgery. *Cureus*. 10(6):e2825.
11. Madan AK, Lanier BJ, Tichansky DS, Ternovits CA. Laparoscopic Roux-en-Y gastric bypass with subtotal gastrectomy. *Obes Surg*. 2005 Oct;15(9):1332–5.
12. Braghetto I, Martinez G, Korn O, Zamorano M, Lanzarini E, Narbona E. Laparoscopic subtotal gastrectomy in morbid obese patients: a valid option to laparoscopic gastric bypass in particular circumstances (prospective study). *Surg Today*. 2018 May;48(5):558–65.



bmi journal
seco-seedo